Extrait du L'encyclopédie neurochirurgicale

http://www.neurochirurgica.org/spip.php?article29

DIFFUSE LOW GRADE GLIOMAS

- Pathology -

Date de mise en ligne : Tuesday 10 March 2015

Description :

Diffuse low-grade gliomas (WHO grade II) are a sub-group of rare and heterogeneous primary brain tumors that usually occur in young patients living a normal life until the onset of a first seizure.

A good understanding of the natural history of these gliomas namely: their steady progression, infiltration along white matter fibers and especially the risk of malignant transformation-which endangers the functional and vital prognosis, associated with the minimization of the risk of treatment, has led to a therapeutic change from the "classic" conservative attitude to a more rigorous therapeutic strategy.

Current goal is to elaborate dynamic and individualized treatment; that is; to define the sequence and timing of each treatment option (single to multiple safe

maximal surgical resections within cortical-to-sub-cortical functional borders, single to multiple chemotherapy and radiotherapy sessions) depending on tumor progression (measured on regular follow up MRI), clinical and neurocognitive status and individual's functional anatomy of the brain (studied via brain mapping and susceptible to reorganization through the phenomena of neuroplasticity) to prevent malignant transformation as long as possible while preserving the quality of life.

Only a multidisciplinary approach to multi-center networks can afford to give a real future to patients with this chronic brain disease, with the possibility to design long-term projects be them socio-professional or at the household level. The next step would be that of early screening in order to provide preventive treatment.

L'encyclopédie neurochirurgicale

Copyright © L'encyclopédie neurochirurgicale

SUMMARY

Diffuse low-grade gliomas (WHO grade II) are a sub-group of rare and heterogeneous primary brain tumors that usually occur in young patients living a normal life until the onset of a first seizure.

A good understanding of the natural history of these gliomas namely: their steady progression, infiltration along white matter fibers and especially the risk of malignant transformation-which endangers the functional and vital prognosis, associated with the minimization of the risk of treatment, has led to a therapeutic change from the "classic" conservative attitude to a more rigorous therapeutic strategy.

Current goal is to elaborate dynamic and individualized treatment; that is; to define the sequence and timing of each treatment option (single to multiple safe maximal surgical resections within cortical-to-sub-cortical functional borders, single to multiple chemotherapy and radiotherapy sessions) depending on tumor progression (measured on regular follow up MRI), clinical and neurocognitive status and individual's functional anatomy of the brain (studied via brain mapping and susceptible to reorganization through the phenomena of neuroplasticity) to prevent malignant transformation as long as possible while preserving the quality of life.

Only a multidisciplinary approach to multi-center networks can afford to give a real future to patients with this chronic brain disease, with the possibility to design long-term projects be them socio-professional or at the household level. The next step would be that of early screening in order to provide preventive treatment.

Key Words (MeSH): Low-grade gliomas, Surgery, Chemotherapy, Radiotherapy, Quality of life, Molecular biology

I - DEFINITION

Low-grade gliomas are primary central nervous system tumors arising from glial cells and comprise of World Health Organization (WHO) grade I and II gliomas (44).

The former include pilocytic astrocytomas, gangliogliomas, subependymal giant cell astrocytomas, dysembryoplastic neuroepithelial tumors, and most recent group considered as mixed neuroglial tumors (44).

There are usually benign pediatric tumors and well -delineated within the brain parenchyma. Surgical excision alone may lead to complete remission for decades and even a real cure.

Conversely, grade II gliomas, namely adult supra-tentorial diffuse low-grade gliomas (DLGG), due to their constant growth, infiltrating nature and inevitable malignant transformation are more difficult to understand.

In essence, DLGGs, which include astrocytomas, oligodendrogliomas and grade II oligoastrocytoma, are heterogeneous entities involving complex brain tumors with different clinical, radiological, histological and molecular characteristics. They should no longer be considered 'benign' tumors, but as 'pre-malignant' cancerous tumors.

Thanks to the understanding of their natural history the therapeutic strategies have changed radically in recent years, currently leading to individualized strategies based on early and repeated therapies - rather than a simple follow up as long advocated (26). Thus, this chapter will be purposely devoted on adult DLGG.

Copyright © L'encyclopédie neurochirurgicale

II - EPIDEMIOLOGY

DLGGs represent approximately 15% of gliomas, with an incidence of approximately 1/100 000 per year, and a prevalence of 9/100 000 (60). The median age of patients is between 35 and 40 years. Indeed, in a recent series of the French Network for the Study of gliomas (Réseau Français d'Etude des Gliomes =REG) on 1091 patients, the median age at diagnosis was 37 years (8).

The sex ratio (male / female) is estimated around 1.32 (60), with a predominance of DLGG in Caucasian men. Exposure to ionizing radiation is the only known environmental risk (64). None of the other risk factors considered in theory (chemicals, mobile phones, hereditary factors, etc ...) have never been demonstrated as critical in the development of a DLGG - whose origin remains unknown. Worth noting is the probable inverse relationship between allergies and risk of developing a glioma.

III - NATURAL HISTORY

DLGGs most often affect young patients leading a normal family, social and professional life. Seizures occur most frequently at presentation of these tumors (71). They are often located within or close to 'eloquent' brain areas involved in sensorimotor, language, visuospatial, memory or cognitive functions.

Despite the intrinsic variability of the biological behavior of these tumors, the natural history is now better known. It has long been claimed that the DLGG tumors were 'benign', with little or no progression.

Recent studies have revealed the constant evolution of DLGG by demonstrating that these tumors:

(i) have a continuous spontaneous growth;

(ii) infiltrate brain parenchyma along the white matter tracts, and beyond the borders of abnormal MRI signal;

(iii) will unavoidably transform into high-grade glioma (46,56) (Figure 1).

<a href="IMG/jpg/fig_1.jpg" type="image/jpeg">

Copyright © L'encyclopédie neurochirurgicale

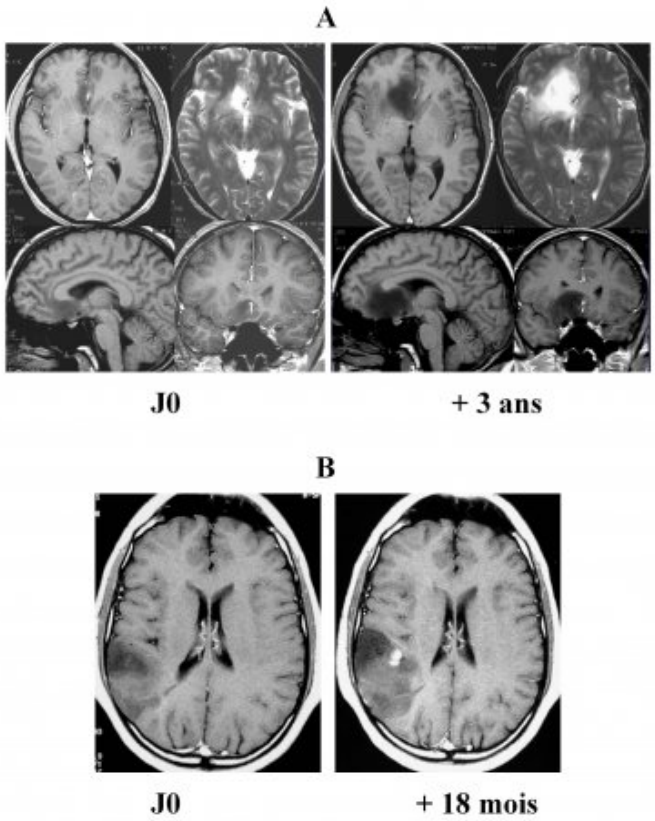

Natural history of DLGGs
A: Successive MRI showing an unavoidable growth - volume is 4 times higher three years later in an asymptomatic patient that is followed up.
B: Malignant transformation with the appearance of contrast enhancement 18 months after the onset of the first seizure in a patient that hasn't received an oncologic treatment.

Thus, the concept of 'benignity of DLGG' has been abandoned.

Two distinct periods make up the natural history of DLGG: a premalignant first phase starting with an occult period followed by a period of clinical and radiological visibility;

a second phase during which a grade II glioma undergoes genetic modification resulting in malignant transformation into a WHO grade III or IV glioma.

Beyond this dichotomous view based on a well distinct histological classification, there is actually a continuum between these evolutionary phases, during which the acquisition of genotypic and phenotypic characteristics of malignancy is progressive. The difficulty thus is to determine, for a given patient at a given moment, at what level (s)he is in the grade II - Grade III / IV transition (61).

In the premalignant period, linear growth of about 4 mm in average diameter per year (calculated on two successive MRI separated by at least three months interval, according to a methodology detailed in the chapter on imaging), was found in all cases, both in symptomatic patients as well as in incidentally discovered DLGG (53).

Copyright © L'encyclopédie neurochirurgicale

In fact, the concept of 'progression free survival' has no meaning in untreated or incomplete surgically resected DLGG since by definition all DLGG continuously growing (although the concept remains valid after of total resection on MRI or in case of stabilization by chemotherapy and / or radiotherapy adjuvant treatments). In this context, conventional radiological criteria originally proposed by McDonald and more recently by the RANO group (75) are not suitable for DLGG, since they are based on the calculation of two diameters and not on the volume (with subsequent comutation of the mean diameter).

If the 'date of birth' (tumour onset) of DLGG is not well known, recent biomathematics models have suggested the existence of two types of gliomas: the first corresponds to very slowly growing tumours that appear during adolescence, and the second type corresponds to slowly growing tumours that appear later, during early adulthood (32).

The long standing asymptomatic nature of DLGG as well as the rarity or extreme discretion of neurological dysfunction is explained by two mechanisms: (i) infiltration of the cerebral parenchyma by isolated tumor cells allowing the persistence of functional tissue within the tumor; (ii) the slow tumor progression enabling the establishment of a cerebral adaptation phenomena of neuroplasticity resulting in a dynamic reorganization of functional networks invaded by glioma (19).

Moreover, not only are these lesions progressively enlarging but they also migrate along the white fibers. Therefore, a DLGG is not a 'tumoral mass' but a chronic disease progressively infiltrating brain parenchyma, particularly subcortical connections. It is this diffusion that eventually induces neurocognitive disorders, because (at least partly) of a very probable disconnection syndrome (27).

Finally, DLGG inexorably evolve towards malignancy. This transformation can be observed clinically and radiologically in a slow or rapid manner, again stressing the biological diversity of DLGG and explaining the possibility of diagnosing them at intermediate stages (ie not fitting perfectly in grades II or III / IV of WHO classification, but for example corresponding to a grade II with foci of anaplasia). The exact mechanisms involved in malignant transformation are currently unknown, preventing predictions of its occurrence at the individual level, even if genetic changes are readily associated (40).

It is worth noting the exceptional degeneration of small volume DLGG (less than 10 cc) (4). Clinically, the functional consequences of such a transformation are significant with onset and / or worsening of seizures, occurrence of neurologic deficits or intracranial hypertension. In addition, is associated radiological acceleration of tumor growth as well as appearance of a contrast enhancement, edema or mass effect and possible necrosis. The affection of the functional outcome results from the involvement of a functional area by three mechanisms which may occur in combination: (i) speed of tumor growth greater than the capacity of brain plasticity; (ii) an increase in the mass effect on the eloquent areas adjacent to the glioma and previously recruited by the phenomenon of neuroplasticity; (iii) destruction of axonal networks infiltrated by the tumor.

In all cases this transformation results in the patient's death, with an overall median survival of less than 8 years for DLGG. Indeed, in a prospective randomized EORTC study involving over 600 patients, in the subgroup of patients with a favorable prognostic score, the median survival was 7.7 years (while it was only 3.2 years in the subgroup of patients with unfavorable prognostic score) (57). More recently, a comparative study between surgical excision and biopsy showed that the median survival was only 5.8 years in the group of patients biopsied (38). These data clearly demonstrate that the spontaneous prognosis of DLGG is relatively poor.
++++

Copyright © L'encyclopédie neurochirurgicale

IV - DIAGNOSIS

1 Clinical features

DLGGs are diagnosed most often in young patients (median age 35-40), who lead a normal family and socio-professional life. Following an asymptomatic period of several years (as evidenced by incidentally discovered DLGGs), partial or generalized seizures represent the presenting symptom in approximately 90% of patients, and appear to correlate with a better prognosis (62). They are drug resistant in about half the cases, particularly seizures originating from the rolandic, paralimbic, temporal and insular areas (33.66). Neurological examination is usually normal, deficits are infrequent and minimal if present. Intracranial hypertension itself is exceptional even with very large tumor volumes, reflecting the slow tumor progression. Indeed, the absence of neurologic deficit, in spite of frequent location of DLGGs in eloquent areas is explained by the very gradual growth and infiltration of glioma over several years before the first episode of seizure - giving the brain all the time to reorganize. These mechanisms of neuroplasticity are subtended by recruiting perilesional areas and / or areas remote to the glioma - within the ipsi-or contralateral hemisphere (16).

But while cognitive impairments have been underestimated for a long time they were frequently detected once an extensive neuropsychological assessment was performed at diagnosis. In fact while it has been traditionally considered that these patients had no neuropsychological deficit, many teams have recently demonstrated the existence of cognitive disturbances and stressed their (s) effect (s) on the quality of life - questioning the dogma of 'patient with a DLGG with normal examination' (1).

These deficits, affecting mostly the processes of attention, working memory, executive function, learning or emotional and behavioral aspects, were found in approximately 90% of patients with brain tumor before treatment, supportive of the a negative impact of DLGG itself (41).

Thus, neurocognition is increasingly integrated as an evaluation criterion in clinical studies of patients with DLGGs. This is why systematic neuropsychological assessment together with rating scales of the quality of life are now recommended. This is for the following reasons:

(i) to search for possible subtle cognitive impairment missed during standard examination using appropriate assessment tools (e.g., the MMSE, although they are not quite exact when applied to patients with DLGGs because it was initially designed for screening of degenerative diseases in the elderly);

(ii) to develop the best individualized treatment strategy based on these results (eg, decision to resort to neoadjuvant chemotherapy rather than surgery first in highly infiltrating DLGG already with significant cognitive impairment);

(iii) to adapt the technique of any surgical procedure (for example, deciding to perform awake surgery with intraoperative mapping of language despite tumor location in the right hemisphere in a right-handed patient, because of discrete but objectives language disorders detected during evaluation, or to select intraoperative tasks on the basis of pre-surgical neuropsychological evaluation);

(iv) to determine a pretreatment cognitive baseline reference, crucial for longer term monitoring particularly post-operatively.

(v) and to plan for postoperative functional rehabilitation as surgery could have induced a transient neurocognitive impairment (25). Finally, note that the occurrence of high-order function impairment could be an early predictor of

Copyright © L'encyclopédie neurochirurgicale

relapse in longitudinal neuropsychological studies.

In summary, in DLGGs, neuropsychological examination enables monitoring of neurological, cognitive and / or behavioral state, aids the therapeutic strategy and can potentially be an early indication of changes in tumor even before their detection by imaging.

2 imaging Features

Morphological Imaging

Although brain CT-scan can show a rather suggestive image (spontaneous hypodensity typically not enhanced after iodine injection, sometimes associated with calcifications), MRI of the brain is currently the gold standard in DLGGs. These tumors usually appear as poorly defined lesions, usually homogeneous, hypo-intense on T1 and hyper-intense signal T2 / FLAIR weighted images. On the contrary, although a typical DLGG doesn't show enhancement, nearly 30% of these tumors may actually be enhanced with gadolinium (low intensity and / or punctiform). In fact, some ill-defined enhancements may remain stable over time. However, the appearance of contrast uptake, especially if nodular is often a sign of malignant transformation (52).

The volume of a DLGG is generally already large at diagnosis, estimated at an average of about 48 cc (8). These tumors are commonly located in functional areas, including frontal (especially at the supplementary motor area, ie just in front of the rolandic area) & insular - in contrast to glioblastomas, situated more posteriorly (28).

The plot of the growth curve of the tumor by comparing its mean diameter (calculated from its volume according to the formula d= $\sqrt[3]{\frac{6Vol}{\pi}}$ $\sqrt[3]{\frac{6Vol}{\pi}}$ on two consecutive MRI done at three months interval) is of significant importance at initial diagnosis, especially in detecting fast-growing gliomas behaving as a true malignancy.

Indeed, a direct statistical correlation was found between the evolving kinetics and the median survival in a subgroup of patients with DLGGs, with a median survival of 253, 210, 91 and 75 months for a growth rate of less than 4 mm / year, 4 to 8 mm / year, 8 to 12 mm / year and more than 12 mm / year, respectively (56).

It is worth noting that, if at the time of the first MRI, two disparaging criteria are met according to the ' UCSF classification' (based on the tumor location in a functional area, the Karnofsky index d 80, age> 50 years, maximum diameter> 4cm) (10), the second MRI will be proposed earlier-six weeks from the first. This same calculation for tumor growth rate will be applicable throughout the follow up and to objectify any possible response to therapy (48,55).

Furthermore, successive MRIs show that; glial cells migrate along the axonal tract, tumor infiltration follow preferentially intrahemispheric white matter fibres (in particular uncinate, arcuate fascicles, and inferior fronto-occipital fascicle for paralimbic glioma) and / or interhemispheric white matter fibres according to their initial location, but also projection fibres such as the pyramidal tract (47).

However, conventional structural MRI is not able to show the boundaries of tumor infiltration. Indeed, it was demonstrated using staged biopsies that DLGGs invaded the parenchyma beyond the abnormal FLAIR signal, with

Copyright © L'encyclopédie neurochirurgicale

tumor cells that could be found up to 2 cm around these anomalies (54). In fact, the use of new metabolic imaging techniques could be used to refine the diagnosis.

++++

Metabolic imaging

MRI spectroscopy (MRS) measures major metabolites in the tumor tissue. The spectrum of a typical DLGG shows high choline, reflecting increased cell membrane turnover, reduced N-acetyl-aspartate, reflecting an increase neuronal loss and myoinositol reflecting glial proliferation. However, these spectral anomalies can also be observed in some non-neoplastic lesions. Although it is not possible to diagnose the degree of glioma based only on MRS due to similarities between the low-grade and high-grade gliomas, the presence of lactate and lipids (reflecting necrosis) is associated with a higher proliferative activity and a more aggressive behavior (35). Despite the limitations mentioned above, MRS is useful for guiding a biopsy and for follow up including patients on treatment (36).

DSC-MRI perfusion sequences (Dynamic Susceptibility Contrast Imaging) enable the calculation of relative Cerebral Blood Volume (rCBV), which correlates with the micro-vasculature. An increased VCSr in DLGGs is predictive of malignant transformation even before the onset of contrast enhancement (12). However, these observations seem limited to astrocytomas because of the higher VCSr in oligodendrogliomas.

DCE-MRI (Dynamic Contrast-Enhanced Imaging) sequences measure the permeability of the blood-brain barrier by calculating a transfer coefficient (Ktrans), which is correlated with the grade of the tumor, although the correlation is not as strong that for VCSr (42).

As for MRI diffusion, the values of the apparent diffusion coefficient (ADC) are lower and more variable in oligodendrogliomas than in astrocytomas. There is no correlation between the diffusion coefficient and the level of choline. Quantitative MRI in oligodendrogliomas with deletion 1p19q shows a more heterogeneous T1-T2 signal, less distinct margins and an increased VCSr compared with gliomas without deletion (6).

Positron Emission Tomography (PET) may also provide additional information in the diagnosis and monitoring of a DLGG (70). The [18F] - fluorodeoxyglucose (FDG) has limited value, due to a low uptake by DLGGs with respect to normal cortex. PET-FDG is basically for the detection of anaplastic transformation of astrocytomas and in the differential between radiation necrosis and tumor recurrence. PET with 11C-Methionine (MET) has the advantage of capturing a TEM correlated with proliferative activity of tumor cells. MET uptake in normal brain tissue is less than that of FDG, allowing better contrast and better delineation of DLGG. In addition, DLGGs with oligodendroglial component further capture MET.

MET-PET may be useful for differentiating DLGGs from non-tumor lesions, to guide stereotactic biopsies, to determine the pre-operative volume and to quantify the response to treatment. However, a cyclotron is required. Recently, 18F-fluoro-ethyl-L-tyrosine (FET) was used to guide biopsies and plan treatment for gliomas. FET has the advantage of a longer half-life than the MET, thereby enabling the manufacturing of the tracer in a center with a cyclotron and its transportation to other institutions. The experience of the FET-PET is still limited compared to the MET-PET, but these tracers seem to show a similar uptake and distribution in brain tumors.

In summary, neuroimaging is useful for diagnosis, to guide biopsy or surgical resection, to plan for radiotherapy and to monitor response to treatment.

Functional Imaging

In terms of exploration of brain function, the development of functional neuroimaging techniques, including functional

Copyright © L'encyclopédie neurochirurgicale

MRI (fMRI), magnetoencephalography, white fiber tractography by diffusion tensor imaging and transcranial magnetic stimulation, has enabled the realization of non-invasive mapping of the whole brain. These methods provide an estimate of the localization of eloquent areas (ie involved in sensorimotor, visual, speech and cognitive) with respect to glial tumor, while providing information about the hemispheric lateralization of speech.

However, it is crucial to note that functional imaging is currently not sufficiently reliable at the individual level to be used in routine clinical practice. This is mainly due to the fact that this imagery is not a direct reflection of the reality of cerebral function, but a very indirect approximation, based on biomathematical reconstructions - explaining why the results may vary depending on the model used. (22)

In fact, with regard to fMRI correlational studies with intraoperative electrophysiology have shown that the sensitivity of the fMRI varied from 59% to 100% for speech (specificity 97% to 0%) (34). Moreover, fMRI is not able to differentiate between essential functional regions (that must be surgically preserved) from involved but non critical regions for a given function (which can be surgically removed, since a functional compensation is possible).

Diffusion tensor imaging a new technique which allows for the tractography of the main white matter tracts, still requires validation. In fact, the use of different models and software from the same data leads to different reconstructions, showing that tractography is not reliable or reproducible. The correlations between this method and intraoperative electrophysiology (direct subcortical electro-stimulation) showed agreement in only 82% of cases. In other words, a negative tractography does not formally rule out the presence of important fibers within the glioma. Furthermore, this technique is able to provide (indirect) anatomical information but by no means does it provide information on the function of subcortical fibres. Therefore it is not currently reasonable to rely on this method for surgical indications or for the planning of surgery, although it is an excellent tool for both education and research (43).

3. Anatomo-pathological Features

As mentioned in the introduction, the WHO classification recognizes grade II astrocytomas, oligodendrogliomas and oligoastrocytoma (44). Morphological criteria differentiate astrocytomas from oligodendrogliomas, even if such a distinction can be problematic, especially in 'mixed' forms - since there are no specific recommendations on the relative proportion of astrocytic and oligodendroglial tissue differentiation enabling the diagnosis of oligoastrocytoma.

Astrocytomas

Diffuse astrocytomas include fibrillar, (most common) protoplasmic and gemistocytic forms; the latter having been set aside because of an increased risk of malignant transformation. Fibrillary astrocytoma may show some nuclear atypia within a fibrillar matrix.

The gemistocytic variant consists of eosinophilic cytoplasms engorged with eccentric rings in more than 20% of tumor cells. Mitotic activity in the grade II astrocytomas is very low. One mitotic activity should not lead to the diagnosis of anaplastic astrocytoma, although a mitotic activity during stereotactic biopsy should raise suspicion.

The most common molecular alteration in astrocytomas is IDH1 mutation reported in approximately 75% of astrocytomas. However, this alteration is found with a similar frequency in oligodendrogliomas thus represents a marker for WHO grade II and III astrocytomas, oligodendrogliomas and oligoastrocytomas. The development of a specific antibody (H09) of IDH1 R132H mutation-is very useful for the diagnosis of astrocytomas, oligodendrogliomas and oligoastrocytomas. H09 covers over 90% of all IDH1 mutations in diffuse gliomas.

Copyright © L'encyclopédie neurochirurgicale

Proliferation index studied using anti-Ki67 / MIB-1 is generally less than 4% in diffuse astrocytoma. Tumor necrosis, capillary endothelial proliferation, vascular thrombosis and high mitotic activity are not consistent with a grade II diffuse astrocytoma. The best immunohistochemical marker is GFAP (Glial Fibrillary Acidic Protein). P53 mutation is present in 50% of diffuse astrocytomas and in 80% of gemistocytic astrocytomas, while the co-deletion 1p19q is rare.

Oligodendrogliomas

Oligodendrogliomas have a moderate cell density and typically have a perinuclear halo giving a 'honeycomb' or 'fried egg' appearance. Occasionally, small tumor cells with eosinophilic cytoplasm are encountered and are termed 'mini-gemistocytes'. Oligodendrogliomas have a dense network of capillaries and frequently contain microcalcifications. Occasional mitotic activity and Ki-67 index / MIB-1 of about 5% are consistent with a grade II oligodendroglioma. There is no specific immunohistochemical marker for oligodendrogliomas.

The molecular characteristic of oligodendrogliomas is the 1p19q co-deletion found in 80% of these tumors, while a p53 mutation occurs in only 5% of the cases. IDH1 somatic mutation is present in 80% of oligodendrogliomas.

Oligoastrocytoma

Oligoastrocytomas should be diagnosed upon detection of significant oligodendroglial and astrocytic components but the inter-observer differences for the diagnosis of oligoastrocytoma remains high. Most oligoastrocytoma present an 1p19q deletion or a p53 mutation. These changes tend to be found in both tumor compartments. Up to 80% oligoastrocytomas carry a somatic IDH1 mutation.

Limitations

A number of limitations need to be underscored (40). First, a high inter-and intra-observer variability been shown and should be taken into account due to a lack of reproducibility of the current WHO classification. This explains why morphological neuropathological examination must be associated with the study of molecular characteristics (61).

In addition, in the context of surgical biopsies, especially stereotactic biopsy, even if they are guided by metabolic imaging and staged, there remains a risk of under grading of tumor.

Indeed, DLGGs are heterogeneous tumors with possible macro-foci and even micro-foci of 'malignant transformation' within a grade II tumor which may not be revealed in the biopsy. Thus, a specimen is only a sample of glioma, a 'false negative' 'grading' can lead to inappropriate therapy. Finally, the current WHO classification does not clearly recognize the existence of a continuum between glioma grade II and III gliomas. The number, size and spatial distribution of foci of potential malignant transformation are not taken into account.
++++

V - PROGNOSTIC FACTORS

Advanced age, the presence of a neurological deficit at diagnosis and poor functional status (Karnofsky score <70) are factors of worst prognosis (13,40,57)

In terms of imaging, a larger tumor volume and DLGGs which cross the midline correlate with a shorter overall

Copyright © L'encyclopédie neurochirurgicale

survival. Thus, a greater than 10 cc and a 30 cc volume a fortiori correlated significantly with a higher risk of rapid malignant transformation and shorter survival (4).

The growth rate is inversely proportional to the survival (56). A recent study showed that the median survival was greater than 15 years for a growth rate of less than 8 mm / year reduced to 5 years for a growth rate of 8 mm / year or more (51).

The correlation between contrast enhancement and prognosis is controversial, but it seems that the occurrence of contrast enhancement and a nodular enhancement are negative factors (52).

Low VCS and low PET-MET uptake correlate with longer overall survival. The correlation between survival and VCSr has been replicated in different institutions (7).

Oligodendrogliomas have a better prognosis than astrocytomas, while oligoastrocytoma have an intermediate prognosis.

MIB-1 index inversely and independently correlated to the survival in multivariate analysis on grade II and grade III astrocytomas. Likewise for grade II and III oligodendrogliomas. The threshold at which the prognosis changes varies with studies between 3% and 8%, but prognosis continues to worsen with an increase in the index.

In grade II astrocytomas, the median survival was 72 months if the MIB-1 index was> 3% and 23 months if> 3%. In a series of grades II and III oligodendrogliomas, the median survival was 3.4 years and 1.1 depending if the index was higher or lower than 5% (15).

At the molecular level, complete deletion of chromosome 1p (with or without deletion of 19p) is favorable prognostic factor (76). The methylation of the MGMT promoter could predict longer survival in patients treated with Temozolomide whereas the value of IDH1 mutation remains controversial.
++++

VI - TREATMENT

1. Therapeutic strategy

The demonstration of the existence of a functional and vital prognosis in less than a decade in young patients leading an active lifestyle at diagnosis, coupled with methodological advances which have enabled a minimization of therapeutic risk, resulted in an early intervention for DLGGs.

Several symptomatic (AEDs) and oncologic treatments (surgical resection, possibly repeated, chemotherapy, radiotherapy) are thus to be considered not in isolation, but in combination, in the view of adapting individualized treatment strategies, and also for each patient at the different phases of disease history.

The purpose of such an attitude is twofold: the preservation and even the improvement of the quality of life and an increased survival time - delaying malignant transformation (26).

Copyright © L'encyclopédie neurochirurgicale

2. Anti-Epileptic Treatment

The management of epilepsy in DLGG has been the subject of recent reviews (62,71). In patients who have had a single attack, immediate antiepileptic treatment reduces the risk of a possible second attack compared to delayed treatment, without major complications with no additional burden on the quality of life.

Older antiepileptic medications, including carbamazepine, phenytoin and valproate have demonstrated their effectiveness against placebo in controlled studies. New medications, including gabapentin, lacosamide, lamotrigine, oxcarbazepine, or topiramate have shown their equivalence but not their superiority compared to carbamazepine, phenytoin and valproate. A randomized trial comparing carbamazepine to the most recent drugs (lamotrigine, gabapentin, oxcarbazepine, or topiramate) showed a longer duration to treatment failure with lamotrigine. Moreover, better cognitive status was also found with lamotrigine.

Levetiracetam, indicated as monotherapy in partial epilepsy, has also demonstrated its equivalence to carbamazepine in a prospective randomized trial.

Levetiracetam may be introduced and increased rapidly, which is an advantage compared to other medications, especially lamotrigine.

It is also available as an injection (eg valproate) with an excellent efficacy / safety ratio in neuro-oncology.

Lacosamide in combination with another treatment appears to be effective and well tolerated.

The enzyme-inducing effect of some antiepileptic medications can lead to an interaction with many chemotherapy drugs (nitrosoureas, paclitaxel, cyclophosphamide, topotecan, irinotecan, thiotepa). Valproate may potentiate the hematologic toxicity associated with chemotherapy.

The decision to possibly stop antiepileptic therapy should be made on a case by case basis depending on the lifestyle of each patient, and must be tapered over a period of about 3 to 6 months

3. Surgery

Impact of surgical resection on survival in DLGG

Surgery is required in all cases to obtain a tissue sample, in order to differentiate tumor subtypes, to define tumor grade and to study its genetics.

Beyond this histo-molecular goal, the aim of surgery is to strive for a maximal resection in order to minimize the risk of malignant transformation and therefore increase median survival while maintaining or even improving the quality of life of these patients.

To that effect, the extent of resection should always be objectified by post-operative MRI. Indeed, a critical point is the precise definition of complete resection of DLGG which is the total ablation all hyperintense regions on FLAIR sequence, verifiable by comparing pre-and post-surgical MRIs. A subtotal resection is considered with a residual

Copyright © L'encyclopédie neurochirurgicale

volume of less than 10cc and partial if it is more than 10cc. Despite the absence of randomized trials, all surgical series based on an objective assessment of postoperative MRI have shown a significant impact of the complete or subtotal resection on overall survival in delaying malignant transformation (2,8,9,30, 37,45,65,69).

Specifically, a recent study compared survival in two cohorts of patients with DLGG. In the first group, patients received a single biopsy and follow-up (biopsy and watchful waiting), with a median survival of only 5.9 years. In the second group, early surgical resection was performed: median survival was not reached in the same period, demonstrating the significant impact of the intervention (38). Thus the largest surgical series about 1097 patients has been reported by the French Network for gliomas Study (REG= Réseau d'étude français des gliomes), showing a median survival of 13 years from the first treatment and 15 years from the first symptom - either overall double when compared to watchful waiting (8).

This is why currently a prospective randomized study would not be ethical. Therefore, due to an increased risk of malignant transformation, lower quality of resection due to progression of tumor infiltration during the follow up, early surgery at diagnosis is currently recommended (once there is evidence of volumetric increase) (21,64). Biopsy (while conscious of the risk of tumor under grading aforementioned) should be reserved exclusively when intervention is contraindicated, particularly in gliomatosis. Surgery for asymptomatic DLGG is now being discussed, as it results in a greater number of total resections due to smaller tumor volume (24).

In conclusion, according to current European recommendations surgical resection represents the first therapeutic option in DLGG (72).

Functional consideration

A recent meta-analysis showed beyond the fact that although the use of intra-operative electrical stimulation mapping techniques significantly increased the percentage of patients with total or subtotal resection, they significantly decreased the rate of permanent postoperative deficits (17).

In this sense, awake surgery is a well tolerated procedure (see Chapter by Zemmoura and Duffau for technical aspects), which allows (i) to expand the indications for surgery in 'eloquent' areas (3) (ii) to identify critical functional cortical and subcortical structures, especially related to sensorimotor, language, visual-spatial, cognitive and emotional processing (iii) to reduce the risk of permanent neurological sequelae to less than 2% (29.63) (iv) to perform resection according to functional boundaries without margins (rather than on purely anatomical or 'oncologic" borders) which gives optimization of the extent of resection (14) (v) and to increase overall survival (23) .

In fact, a recent study showed that the use of functional mapping in awake patients at high risk because of the localization of DLGG in eloquent areas resulted in very significant increase in the long-term survival through an increase in the extent of resection (11).

Moreover, awake surgery in 'non-functional' areas can lead to a 'supra-total' resection - that is, to remove a safety margin around the FLAIR hyperintensity visible on MRI as tumor cells infiltrate within 1 to 2 cm (54), with a very significant impact on the malignant transformation (77). When total resection is not feasible for functional reasons, one or more re-do interventions can be considered, with an impact on overall survival while preserving brain function (8.50).

Indeed, awake surgery has equally enabled the performance of one or more reoperations with functional preservation and improvement in the extent of resection, including eloquent areas, through mechanisms of brain plasticity (20) (Figure 2).

Copyright © L'encyclopédie neurochirurgicale

<a href="IMG/jpg/fig_2.jpg" type="image/jpeg">

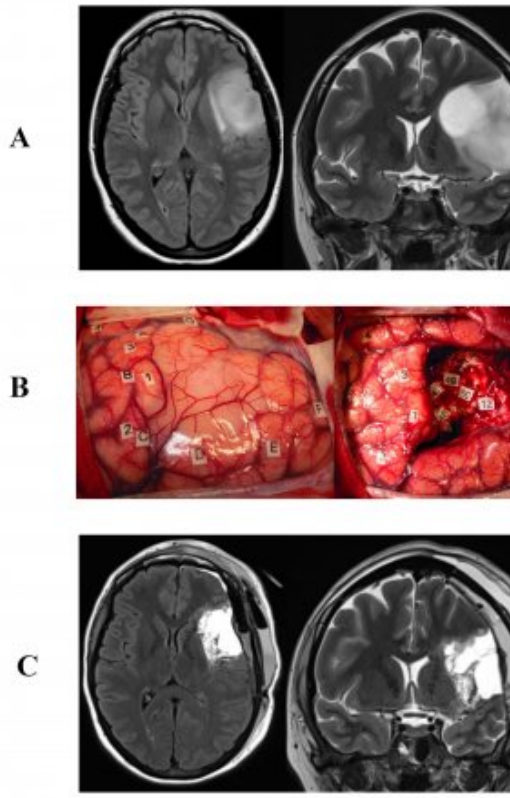

Resection of a DLGG infiltrating the left opercular region ("Broca's area") with invasion of the insula.
A: FLAIR MRI sequences, axial (left) and coronal T2 (right) showing a typical image of a left operculo-insular DLGG in a right-handed 35 year old patient who experienced an inaugural seizure. Neurological examination was normal preoperatively, but the neuropsychological assessment objectified disorders verbal working memory.
B: Intraoperative photographs before (left) and after (right) surgical resection performed according to cortical and subcortical intraoperative functional boundaries in an awake patient. The letters symbolize the tumor boundaries identified through an intraoperative ultrasound system. The numbers correspond to "eloquent" areas as follows:

- *Cortical areas 1 and 3 (speech arrest at the ventral premotor cortex); 2: primary motor area of the face; 4: anomic area (posterior superior temporal gyrus);*
- *Subcortical areas: 48: anarthria generated by stimulation of the anterior portion of the lateral upper longitudinal tract (ending at the ventral premotor cortex); 49, 46, 47: semantic paraphasias induced by stimulation of the inferior fronto-occipital tract (courses in the temporal stem and frontal lobe, terminating at the dorsolateral prefrontal cortex); 50: "Negative motor" network resulting in interruption of movement during stimulation and projecting into the anterior limb of the internal capsule; 12: perseverations generated by stimulation of the head of the caudate nucleus. C: FLAIR sequences: axial (left) and coronal T2 (right) on early postoperative MRI (done six hours after surgery), demonstrating complete resection. The diagnosis of WHO grade II glioma was confirmed histologically. After a transient worsening in speech requiring speech therapy a few weeks at home, the patient resumed a normal social and professional life - with improved neuropsychological assessment performed 3 months after surgery in comparison to the preoperative assessment. No adjuvant cancer treatment was given, but clinical follow up and regular MRI was introduced.*

Moreover, wide resection, especially if complete on imaging, improve epilepsy control in approximately 80% of cases, particularly in patients with prolonged preoperative epilepsy and in cases of insular gliomas (33).

Finally, with an individualized functional and cognitive rehabilitation in the early postoperative period,

Copyright © L'encyclopédie neurochirurgicale

neuropsychological improvements have even been shown in 30% of patients following resection - especially working memory (73). It must be emphasized that a recent randomized trial showed that cognitive rehabilitation had a positive impact on cognitive symptoms in the short and long-term as well as mental fatigue among patients with glioma patients (31).

In summary, early more radical surgery as possible, should be considered as first-line therapy in DLGG because of the favorable impact on both survival and quality of life.

4. Chemotherapy

The usefulness of chemotherapy in operated and irradiated patients has been well established, especially for oligodendrogliomas. The combination Procarbazine, CCNU and vincristine (PCV) as well as Temozolomide resulted in 45-62% response rate at 10-24 months duration objectified on relatively similar imaging- albeit with a less toxicity and better tolerance on Temozolomide (58).

In addition, a functional benefit, particularly due to a favorable impact on seizures, is frequently observed not only in patients with significant radiological regression but also in tumors stabilized by chemotherapy**.**

Chemotherapy with PCV or Temozolomide has also been administered postoperatively before radiotherapy, particularly in patients with partial resection, intractable epilepsy and / or rapid progression on imaging control. The majority of patients were classified as 'responders' most of the time with a stabilization or volumic regression, although usually partial. This effect may be delayed until 24-30 months and may persist despite discontinuation of chemotherapy (59).

Even though the chances of response are greater for oligodendroglial tumors, they are not insignificant for astrocyte or mixed tumors.

Most patients with drug-resistant epilepsy may benefit from a reduction in the frequency and intensity of crises, including in the absence of volume regression on MRI.

It is worth reemphasizing that the conventional MacDonald criteria radiological are not suitable for monitoring patients treated for DLGG, especially in the absence of contrast enhancement, and evolutionary kinetic calculations should be made from now on the basis MRI T2 / FLAIR sequences after volumic measurements (55).

Neoadjuvant chemotherapy may also be given as first line treatment in inoperable tumors due to massive infiltration of functional zones. This chemotherapy may allow regression of infiltration and open the door to a second surgical resection while preserving the quality of life (5).

Although the impact of 1p19q deletion on the response rate to chemotherapy remains a subject of controversy, response duration seems longer in case of co-deletion

The lowest doses of Temozolomide administered daily 3 weeks out of 4 could provide an advantage compared to the usual doses given 5 days per month, especially in unmethylated gliomas, but at the cost of a possible increase in toxicity.

Copyright © L'encyclopédie neurochirurgicale

Quality of life does seem generally unaffected by taking Temozolomide for months or years (5).

5. Radiotherapy

The role of radiotherapy in the treatment of DLGG has been completely revised in recent years; while early irradiation has long been advocated, irradiation should now be postponed. Indeed, a prospective randomized study (EORTC 22845) comparing early versus delayed radiotherapy showed that although progression-free survival was increased during early radiotherapy, no significant difference was eventually found on overall survival because of the time of irradiation (74).

Furthermore, patients treated with whole-brain irradiation have seen a higher incidence of leukoencephalopathy and cognitive deficits compared to those with focal radiotherapy. A recent study also demonstrated in patients with a neuropsychological follow-up of 12 years without tumor recurrence that those without irradiation had preserved cognitive function while those irradiated showed a worsening of attention and executive functions as well as a slowdown in information processing speed in 57% of cases (18).

A multivariate analysis favored a predominant involvement of attention functions. In addition, two randomized trials have studied different doses of irradiation: the EORTC study (45 versus 59.4 Gy) and NCCTG (50.4 versus 64.8 Gy) showed no benefit of high-dose compared with lower doses (39, 67). On the contrary, increased toxicity was induced by higher doses, with an incidence of radiation necrosis of 2.5% within 2 years post-radiotherapy or a negative impact on the quality of life, particularly as a result of greater fatigue, insomnia and emotional disorders.

Therefore, radiation therapy is currently used only in case of treatment failure after surgery (s) and chemotherapy (s), at a lower dose and focally - except in certain cases of intractable epilepsy, since irradiation could allow control of the latter (62).

Finally, it is important to stress that the RTOG 9802 trial compared radiotherapy alone versus radiotherapy with PCV chemotherapy (68). In the radiotherapy alone arm, since two-thirds of patients had received chemotherapy due to secondary progression, thus finally, the study can be regarded as a comparison of early chemotherapy versus chemotherapy on tumor progression. Progression-free survival was improved, but not overall survival. However, beyond 2 years, the addition of PCV chemotherapy to radiation reduced the risk of death by 48% and the risk of progression by 55%, suggesting a delayed effect of chemotherapy. NCI grade 3-4 toxicity was however higher in patients treated with radiotherapy and chemotherapy (67% versus 9%).

6. Towards an individualized and serial therapeutic strategy

The optimal management needs to be tailored according to the complex biological behavior of each DLGG. In classical literature, the vast majority of studies have investigated the role of a single treatment in isolation (role of surgery, chemotherapy or radiotherapy) without an overall vision of the entire strategy.

The goal now is to evolve towards a holistic approach, based on the anticipation of an individualized and long-term multi-therapeutic approach while adapting to real-time strategy over the years by referring to the clinical, radiological, and histo-molecular updates made possible through regular monitoring *ad vitam aeternam*.

Copyright © L'encyclopédie neurochirurgicale

Such a dynamic attitude challenges the usual (traditional) care in many ways: by proposing early treatment, repeated therapy (e.g. 2 to 4 surgical resection several years apart, or periods of chemotherapy intercalated by simple monitoring, etc.); modifying 'classical order' of treatments (e.g., preoperative neoadjuvant chemotherapy followed by surgery, no early radiotherapy, etc); and all aiming at ultimate optimization of both median survival and quality of life.

To that effect, beyond the risk / benefit ratio of each treatment considered alone, the impact of the global therapeutic strategy on the cumulative time of optimal quality of life versus time to malignant transformation should be systematically taken into account - not just survival regardless of the functional status of the patient. In other words, the individualized management should be based on understanding the interactions between the natural history of DLGG, mechanisms of reactionary neuroplasticity and onco-functional modulation induced by multiple therapies (Figure 3) (21 , 26).

<a href="IMG/gif/fig_3.gif" type="image/gif">

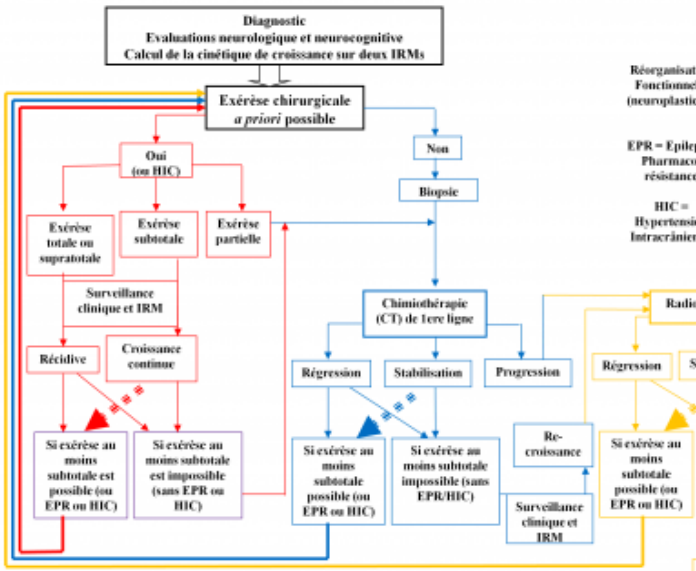

Organigramme for the management of DLGG (modified from 21)

++++

VII - CONCLUSIONS AND PERSPECTIVES

Better knowledge of the natural history of DLGG (growth, infiltration and inevitable degeneration) associated with a risk minimization of each treatment has transformed the 'classic' abstentionist attitude into a resolutely therapeutic attitude.

The goal from now on is towards the development of dynamic and tailored strategy for each patient, namely to determine the sequence and timing of each treatment (single to multiple safe maximal surgical resections within cortical-to-sub-cortical functional borders or single to multiple chemotherapy and radiotherapy sessions) depending on the tumor progression (measured on regular follow up MRI scan), and the clinical and neuropsychological condition and functional brain anatomy of the individual (studied by brain mapping methods and capable of reorganizing through the mechanisms of neuroplasticity) so as to prevent malignant transformation as long as possible while preserving the quality of life.

Only a multidisciplinary approach to multi-center networks can afford to give a real future to patients with this chronic brain disease, with the possibility to design long-term projects be them socio-professional as well as at household level- especially those with plans to become pregnant. The next step would be that of early screening in order to

Copyright © L'encyclopédie neurochirurgicale

provide preventive treatment(49)..

VIII - BIBLIOGRAPHIE

1. Aaronson NK, Taphoorn MJ, Heimans JJ, et al. Compromised health-related quality of life in patients with low-grade glioma. J Clin Oncol 2011;29:4430-5.B2
2. Ahmadi R, Dictus C, Hartmann C, et al. Long-term outcome and survival of surgically treated supratentorial low-grade glioma in adult patients. Acta Neurochir 2009;151:1359-1365.B2
3. Benzagmout M, Gatignol P, Duffau H. Resection of World Health Organization grade II gliomas involving Broca's area: methodological and functional considerations. Neurosurgery 2007;61:741-752.C4
4. Berger MS, Deliganis AV, Dobbins J, Keles GE. The effect of extent of resection on recurrence in patients with low grade cerebral hemisphere gliomas. Cancer 1994;74:1784-1791.C3
5. Blonski M, Taillandier L, Herbet G, et al. Combination of neoadjuvant chemotherapy followed by surgical resection as a new strategy for WHO grade II gliomas: a study of cognitive status and quality of life. J Neurooncol. 2012;106:353-366.C3
6. Brown R, Zlatescu M, Sijben A, et al. The use of magnetic resonance imaging to noninvasively detect genetic signatures in oligodendroglioma. Clin Cancer Res 2008;14:2357-2362.C4
7. Caiseras GB, Chleang S, Babb J et al. Relative cerebral blood volume measurements of Low Grade Gliomas predict patients outcome in a multi-institution setting. Eur J. Radiol 2010;73:215-220.C4
8. Capelle L, Fontaine D, Mandonnet E, et al. Spontaneous and therapeutic prognostic factors in adult hemispheric WHO grade II gliomas: a series of 1097 cases. J Neurosurg 2013;118:1157-1168.B2
9. Chaichana KL, McGirt MJ, Laterra J, et al. Recurrence and malignant degeneration after resection of adult hemispheric low-grade gliomas. J Neurosurg 2010;112,10-17.C4
10. Chang EF, Smith JS, Chang SM, et al. Preoperative prognostic classification system for hemispheric low-grade gliomas in adults. J Neurosurg 2008;109:817-824.B2
11. Chang EF, Clark A, Smith JS, et al. Functional mapping-guided resection of low-grade gliomas in eloquent areas of the brain: improvement of long term survival. J Neurosurg 2011;114, 566-573.C3
12. Danchaivijitr N, Waldman AD, Tozer DJ, et al. Low-grade gliomas: do changes in rCBV measurements at longitudinal perfusion-weighted MR imaging predict malignant transformation? Radiology 2008;247: 170-178.C4
13. Daniels TB, Brown PD, Felten SJ, et al. Validation of EORTC prognostic factors for adults with low-grade glioma: a report using intergroup 86-72-51. Int J Radiat Oncol Biol Phys 2011;81:218-224.B2
14. de Benedictis A, Moritz-Gasser S, Duffau H. Awake mapping optimizes the extent of resection for low-grade gliomas in eloquent areas. Neurosurgery 2010;66:1074-1084.C3
15. Dehgani F, Schachenmayr W, Laun A, Korf H. Prognostic implication of histopathological, immunohistochemical and clinical features of oligodendrogliomas: a study of 89 cases. Acta Neuropathol 1998;95:493-504.C4
16. Desmurget M, Bonnetblanc F, Duffau H. Contrasting acute and slow growing lesions: a new door to brain plasticity. Brain 2007;130:898-914.NA
17. de Witt Hamer PC, Gil Robles S, Zwinderman A. Impact of intraoperative stimulation brain mapping on glioma surgery outcome: a meta-analysis. J Clin Oncol 2012;30: 2559-2565.A1
18. Douw L, Klein M, Fagel SS, et al. Cognitive and radiological effects of radiotherapy in patients with low-grade glioma: long-term follow-up. Lancet Neurol 2009;8:810-818.A1
19. Duffau H. Lessons from brain mapping in surgery for low-grade glioma: insights into associations between tumour and brain plasticity. Lancet Neurol 2005;4:476-486.NA
20. Duffau H. Brain plasticity and tumors. Adv Tech Stand Neurosurg 2008;33:3-33.NA
21. Duffau H. Surgery of low-grade gliomas: towards a "functional neurooncology". Curr Opin Oncol 2009;21:543-549.NA
22. Duffau H. Brain Mapping: From Neural Basis of Cognition to Surgical Applications. Duffau H. (Ed.), Springer Wien New York, 2011.NA
23. Duffau H. The challenge to remove diffuse low grade gliomas while preserving brain functions. Acta Neurochir (Wien) 2012;154:569-574.NA
24. Duffau H. Awake surgery for incidental WHO grade II gliomas involving eloquent areas. Acta Neurochir (Wien)

2012;154:575-584.C4
25. Duffau H. Cognitive assessment in glioma patients. J Neurosurg 2013;119:1348-1349.NA
26. Duffau H. Diffuse Low Grade Glioma in Adults: Natural History, Interaction with the Brain, and New Individualized Therapeutic Strategies. Duffau H. (Ed.), Springer London, 2013.NA
27. Duffau H. The huge plastic potential of adult brain and the role of connectomics: New insights provided by serial mappings in glioma surgery. Cortex, in press.NA
28. Duffau H, Capelle L. Preferential brain locations of low grade gliomas. Cancer 2004;100:2622-2626.B2
29. Duffau H, Gatignol P, Mandonnet E, Capelle L, Taillandier L. Intraoperative subcortical stimulation mapping of language pathways in a consecutive series of 115 patients with grade II glioma in the dominant hemisphere. J Neurosurg 2008; 109: 461-471.C4
30. Duffau H, Lopes M, Arthuis F, et al. Contribution of intraoperative electrical stimulations in surgery of low grade gliomas: a comparative study between two series without (1985-96) and with (1996-2003) functional mapping in the same institution. J Neurol Neurosurg Psychiatry 2005;76:845-851.B2
31. Gehring K, Sitskoorn MM, Gundy CM, et al. Cognitive rehabilitation in patients with gliomas: a randomized, controlled trial. J Clin Oncol 2009;27:3712-3722.A1
32. Gerin C, Pallud J, Grammaticos B, et al. Improving the time-machine: estimating date of birth of grade II gliomas. Cell Prolif 2012;45:76-90.C4
33. Ghareeb F, Duffau H. Intractable epilepsy in paralimbic Word Health Organization Grade II gliomas: should the hippocampus be resected when not invaded by the tumor? J Neurosurg 2012;116:1126-1234.B2
34. Giussani C, Roux FE, Ojemman J, et al. Is preoperative functional magnetic resonance imaging reliable for language areas mapping in brain tumor surgery? Review of language functional magnetic resonance imaging and direct cortical stimulation correlation studies. Neurosurgery 2010;66:113-120.NA
35. Guillevin R, Menuel C, Duffau H, et al. Proton magnetic resonance spectroscopy predicts proliferative activity in diffuse low-grade gliomas. J Neurooncol 2008;87:181-187.C4
36. Guillevin R, Menuel C, Taillibert S, et al. Predicting the outcome of grade II glioma treated with temozolomide using proton magnetic resonance spectroscopy. Br J Cancer 2011;104:1854-1861.C4
37. Ius T, Isola M, Budai R, et al. Low-grade glioma surgery in eloquent areas: volumetric analysis of extent of resection and its impact on overall survival. A single-institution experience in 190 patients. J Neurosurg 2012;117:1039-1052.C4
38. Jakola AS, Myrmel KS, Kloster R, et al: Comparison of a strategy favoring early surgical resection vs a strategy favoring watchful waiting in low-grade gliomas. JAMA 308:1881-1888, 2012.B2
39. Karim AB, Maat B, Hatlevoll R, et al. A randomized trial on dose-response in radiation therapy on low-grade cerebral glioma. European Organization for Research and Treatment of Cancer (EORTC) Study 22844. Inj J Radiat Oncol Biol Phys 1996;36:549-556.A1
40. Kim YH, Nobusawa S, Mittelbronn M, et al. Molecular classification of low-grade diffuse gliomas. Am J Pathol 2010;177:2708-2714.B2
41. Klein M, Duffau H, De Witt Hamer PC. Cognition and resective surgery for diffuse infiltrative glioma: an overview. J Neurooncol 2012;108:309-318.NA
42. Law M, Yang S, Babb JS, et al. Comparison of cerebral blood volume and vascular permeability from dynamic susceptibility contrast-enhanced perfusion MR imaging with glioma grade. AJNR Am J Neuroradiol 2004; 25:746-755.C4
43. Leclercq D, Duffau H, Delmaire C, et al. Comparison of diffusion tensor imaging tractography of language tracts and intraoperative subcortical stimulations. J Neurosurg 2010;112:503-511.C4
44. Louis D, Ohgaki H, Wiestler O, Cavenee W, eds. World Health Organization Classi cation of Tumors of the Central Nervous System, 4 edn. Lyon: IARC, 2007.NA
45. MacGirt MJ, Chaichana KL, Attenello FJ, et al. Extent of surgical resection is independently associated with survival in patients with hemispheric infiltrating low-grade gliomas. Neurosurgery 2008;63:700-707.C3
46. Mandonnet E, Delattre JY, Tanguy ML, et al. Continuous growth of mean tumor diameter in a subset of grade II gliomas. Ann Neurol 2003;53:524-528.NA
47. Mandonnet E, Capelle L, Duffau H. Extension of paralimbic low-grade gliomas: toward an anatomical classification based on white matter invasion patterns. J Neurooncol 2006;78:179-185.NA
48. Mandonnet E, Pallud J, Fontaine D, et al. Inter- and intrapatients comparison of WHO grade II glioma kinetics

before and after surgical resection. Neurosurg Rev 2010;33, 91-96.NA
49. Mandonnet E, De Witt Hamer PC, Pallud J, et al. Silent diffuse low-grade glioma: towards screening and preventive treatment? Cancer, in press.NA
50. Martino J, Taillandier L, Moritz-Gasser S, et al. Re-operation is a safe and effective therapeutic strategy in recurrent WHO grade II gliomas within eloquent areas. Acta Neurochir (Wien) 2009;151:427-436.C3
51. Pallud J, Mandonnet E, Duffau H, et al. Prognostic value of initial magnetic resonance imaging growth rates for World Health Organization grade II gliomas. Ann Neurol 2006;60:380-383.B2
52. Pallud J, Capelle L, Taillandier L, et al. Prognostic signi cance of imaging contrast enhancement for WHO grade II gliomas. Neuro Oncol 2009; 11:176-182.C3
53. Pallud J, Fontaine D, Duffau H, et al. Natural history of incidental World Health Organization grade II gliomas. Ann Neurol 2010;68:727-733.NA
54. Pallud J, Varlet P, Devaux B, et al. Diffuse low-grade oligodendrogliomas extend beyond MRI-defined abnormalities. Neurology 2010;74:1724-1731.C4
55. Pallud J, Taillandier L, Capelle L, et al. Quantitative morphological MRI follow-up of low-grade glioma: a plea for systematic measurement of growth rates. Neurosurgery 2012;71:729-740.NA
56. Pallud J, Blonski M, Mandonnet E, et al. Velocity of tumor spontaneous expansion predicts long-term outcomes for diffuse low-grade gliomas. Neuro-Oncology 2013;15:595-606.B2
57. Pignatti F, van den Bent M, Curran D, et al. Prognostic factors for survival in adult patients with cerebral low-grade glioma. J Clin Oncol 2002;20:2076-2084.A1
58. Quinn JA, Reardon DA, Friedman AH, et al. Phase II trial of temozolomide in patients with progressive low-grade glioma. J Clin Oncol 2003;21:646-651.A1
59. Ricard D, Kaloshi G, Amiel-Benouaich A, et al. Dynamic history of low-grade gliomas before and after temozolomide treatment. Ann Neurol 2007;61:484-490.B2
60. Rigau V, Zouaoui S, Mathieu-Daudé H, et al. French Brain Tumor DataBase: 5-year histological results on 25756 cases. Brain Pathol 2011;21:633-644.B2
61. Rigau V. Histological Classification. In Diffuse Low Grade Glioma in Adults: Natural History, Interaction with the Brain, and New Individualized Therapeutic Strategies. Duffau H. (Ed.), Springer London, 2013.NA
62. Rudà R, Bello L, Duffau H, et al. Seizures in low-grade gliomas: natural history, pathogenesis, and outcome after treatments. Neuro-Oncology 2012;14:iv55-iv64.NA
63. Sanai N, Mirzadeh Z, Berger M.S. Functional outcome after language mapping for glioma resection. N Engl J Med 2008;358:18-27.C3
64. Sanai N, Chang S, Berger MS. Low-grade gliomas in adults. J Neurosurg 2011;115:948-965.NA
65. Schomas DA, Lack NN, Rao RD, et al. Intracranial low-grade gliomas in adults: 30-year experience with long-term follow-up at Mayo Clinic. Neuro Oncol 2009;11:437-445.C4
66. Schucht P, Ghareeb F, Duffau H. Surgery for low-grade glioma infiltrating the central cerebral region: location as a predictive factor for neurological deficit, epileptological outcome, and quality of life. J Neurosurg 2013;119:318-323.C3
67. Shaw E, Arusell R, Scheithauer B, et al. Prospective randomized trial of low- versus high-dose radiation therapy in adults with supratentorial low-grade glioma: initial report of a North Central Cancer Treatment Group/ Radiation Therapy Oncology Group/Eastern Cooperative Oncology Group study. J Clin Oncol 2002;20:2267-2276.A1
68. Shaw EG, Wang M, Coons SW, et al. Final report of Radiation Therapy Oncology Group (RTOG) protocol 9802: radiation therapy (RT) versus RT + procarbazine, CCNU and vincristine (PCV) chemotherapy for adult low grade gliomas (LGG). J Clin Oncol 2012;30:3065-3070. A1
69. Smith JS, Chang EF, Lamborn KR, et al. Role of extent of resection in the long-term outcome of low-grade hemispheric gliomas. J Clin Oncol 2008;26:1338-1345.B2
70. Smits A, Baumert BG. The clinical value of PET with amino acid tracers for gliomas WHO grade II. Int J Mol Imaging. 2011;2011:372509.NA
71. Smits A, Duffau H. Seizures and the natural history of World Health Organization grade II gliomas: a review. Neurosurgery 2011;68:1326-1333.NA
72. Soffietti R, Baumert B, Bello L, et al. Guidelines on management of low grade gliomas: report of an EFNS-EANO task force. Eur J Neurol 2010;17:1124-1133.NA
73. Teixidor P, Gatignol P, Leroy M, et al. Assessment of verbal working memory before and after surgery for

Copyright © L'encyclopédie neurochirurgicale

low-grade glioma. J Neurooncol 2007;81:305-313.C3
74. van den Bent MJ, Afra D, de Witte O, et al. Long-term efficacy of early versus delayed radiotherapy for low-grade astrocytoma and oligodendroglioma in adults: the EORTC 22845 randomised trial. Lancet 2005;366:985-990.A1
75. van den Bent M, Wefel J, Schiff D, et al. Response assessment in neuro-oncology (a report of the RANO group): assessment of outcome in trials of diffuse low-grade gliomas. Lancet Oncol. 2011;12:583-593.NA
76. Weller M, Berger H, Hartmann C, et al. Combined 1p/19q loss in oligodendroglial tumors: predictive or prognostic biomarker ? Clin Cancer Res 2007;13:6933-6937.B2
77. Yordanova Y, Moritz-Gasser S, Duffau H. Awake surgery for WHO grade II gliomas within "noneloquent" areas in the left dominant hemisphere: toward a "supratotal" resection. J Neurosurg 2011;115:232-239.B2
++++

LEGEND OF THE FIGURES

Figure 1: Natural history of DLGGs

A: Successive MRI showing an unavoidable growth - volume is 4 times higher three years later in an asymptomatic patient that is followed up.

B: Malignant transformation with the appearance of contrast enhancement 18 months after the onset of the first seizure in a patient that hasn't received an oncologic treatment.

Figure 2: Resection of a DLGG infiltrating the left opercular region ('Broca's area') with invasion of the insula.

A: FLAIR MRI sequences, axial (left) and coronal T2 (right) showing a typical image of a left operculo-insular DLGG in a right-handed 35 year old patient who experienced an inaugural seizure. Neurological examination was normal preoperatively, but the neuropsychological assessment objectified disorders verbal working memory.

B: Intraoperative photographs before (left) and after (right) surgical resection performed according to cortical and subcortical intraoperative functional boundaries in an awake patient. The letters symbolize the tumor boundaries identified through an intraoperative ultrasound system. The numbers correspond to 'eloquent' areas as follows:

- Cortical areas 1 and 3 (speech arrest at the ventral premotor cortex); 2: primary motor area of the face; 4: anomic area (posterior superior temporal gyrus);

- Subcortical areas: 48: anarthria generated by stimulation of the anterior portion of the lateral upper longitudinal tract (ending at the ventral premotor cortex); 49, 46, 47: semantic paraphasias induced by stimulation of the inferior fronto-occipital tract (courses in the temporal stem and frontal lobe, terminating at the dorsolateral prefrontal cortex); 50: 'Negative motor' network resulting in interruption of movement during stimulation and projecting into the anterior limb of the internal capsule; 12: perseverations generated by stimulation of the head of the caudate nucleus.

C: FLAIR sequences: axial (left) and coronal T2 (right) on early postoperative MRI (done six hours after surgery), demonstrating complete resection. The diagnosis of WHO grade II glioma was confirmed histologically. After a transient worsening in speech requiring speech therapy a few weeks at home, the patient resumed a normal social and professional life - with improved neuropsychological assessment performed 3 months after surgery in comparison to the preoperative assessment. No adjuvant cancer treatment was given, but clinical follow up and regular MRI was introduced.

Figure 3: Organigramme for the management of DLGG (modified from 21)

Copyright © L'encyclopédie neurochirurgicale